

Increased cell proliferation in the ileal pouch mucosa of patients with familial adenomatous polyposis

Pieter Friederich

Radboud University Nijmegen Medical Centre, The Netherlands

Introduction

- Incidence of pouch adenomas in FAP patients
7 – 57%
- Follow up after ileal pouch anal anastomosis (IPAA)
is associated with increasing adenoma occurrence
- 14 cases of ileal pouch cancer in FAP patients
- Changes in pouch mucosa and pouch ecology have
been reported

Aim

To investigate changes in ileal pouch cell kinetics:

- Proliferation
- Apoptosis

Methods

- 32 FAP patients with IPAA
- Biopsies:
 - Non polypoid tissue from the afferent ileal loop and pouch
 - Stretched on filter paper with a dissection microscope
- Proliferation
 - Immunohistochemistry for MIB-1 (Ki-67)
 - At least 3 full crypts were counted per patient and expressed as labeling index
 - Pictures from the tissue sections were visually compared in random pairs by 5 observers

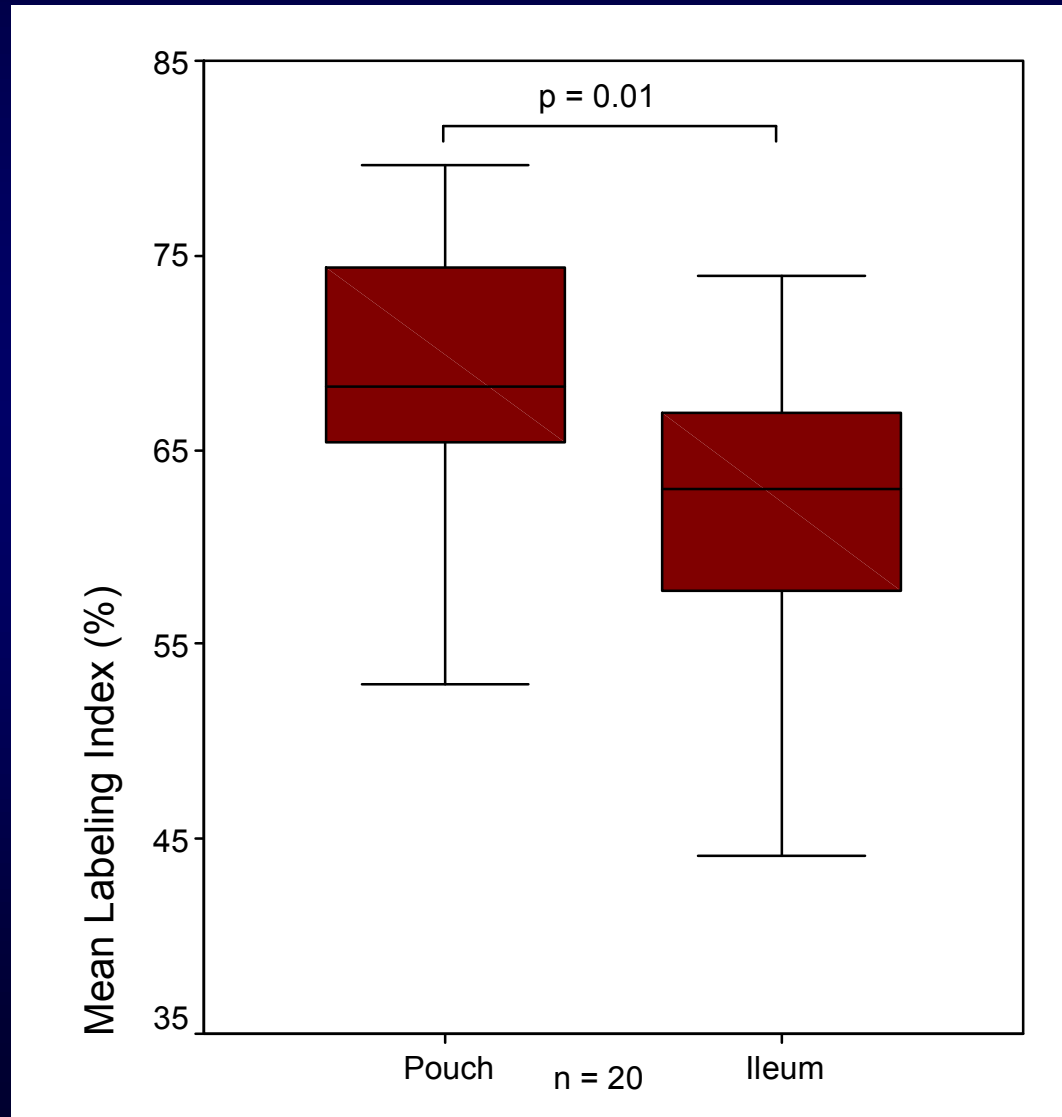
Methods

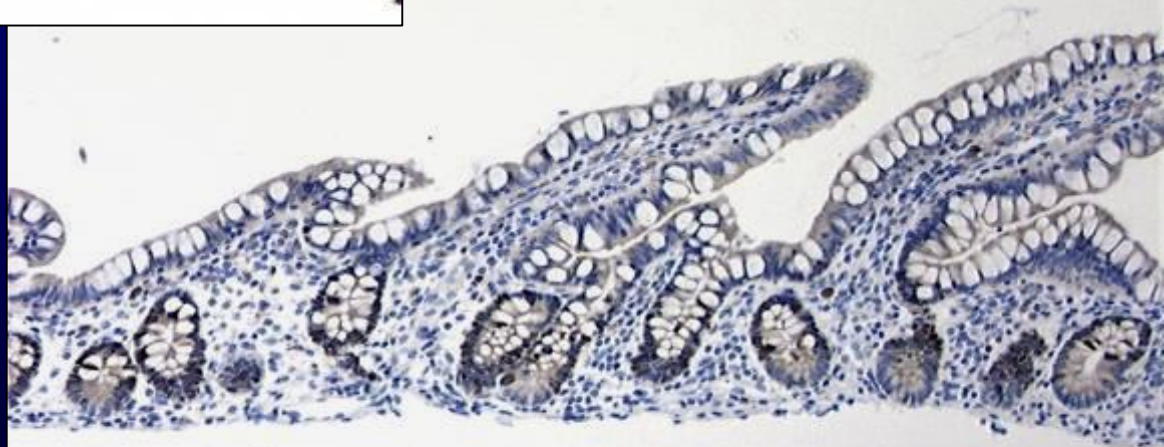
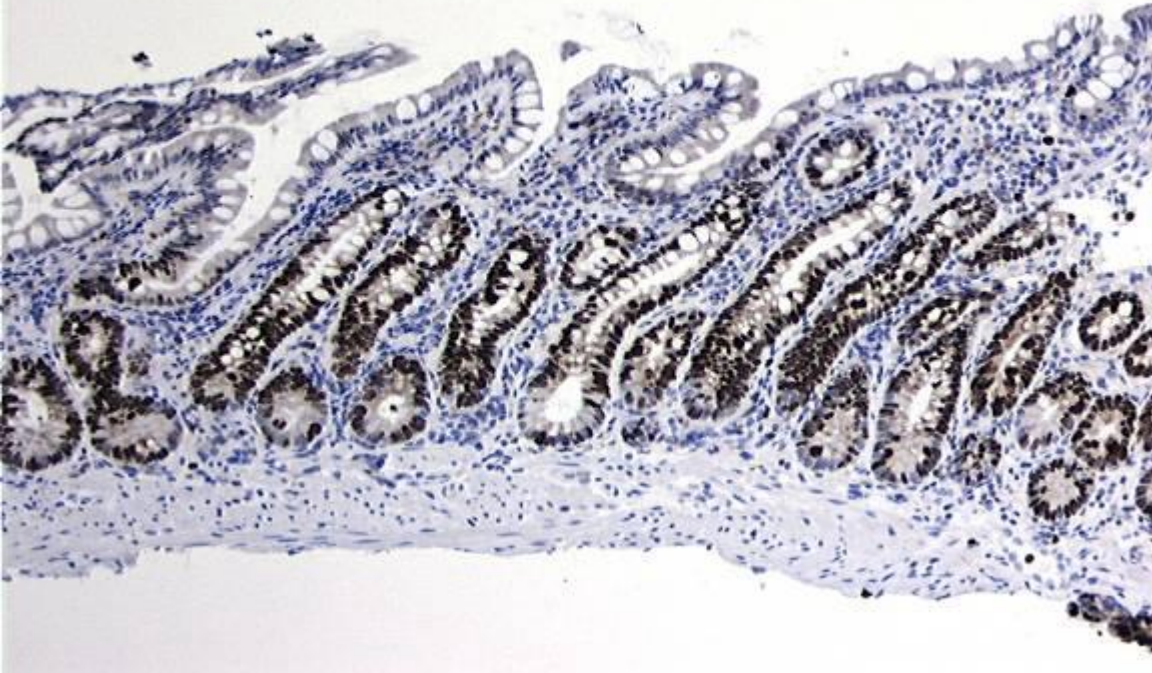
- Apoptosis
 - Immunohistochemistry for M30 (CK18)
 - Expressed as number of positive cells per mm² tissue
- Colonic metaplasia and pouch inflammation
 - H&E stained tissue sections
- Statistical analysis
 - Wilcoxon matched-pairs signed-rank test
 - Sign test
 - Cohen's kappa

Patient characteristics

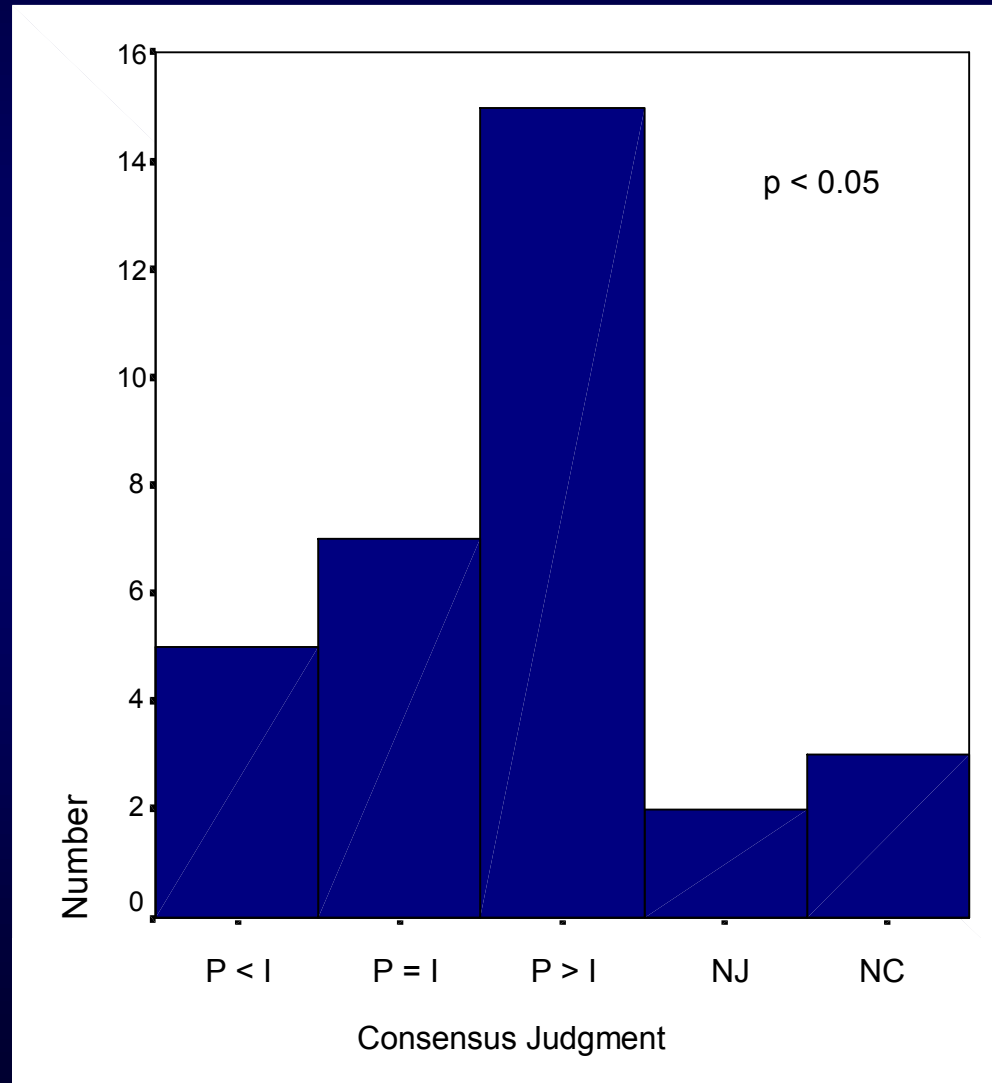
Number of patients	32
Male (%)	19 (59%)
Median age (range)	32 (16-72)
Median age at surgery (range)	24 (10-55)
Median follow-up time after IPAA (range)	8 (1-18)
No. of patients with adenoma	24 (75%)
Spigelman stage	
0	8 (25%)
I	4 (12%)
II	14 (44%)
III	6 (19%)

Cell Proliferation: quantitative method

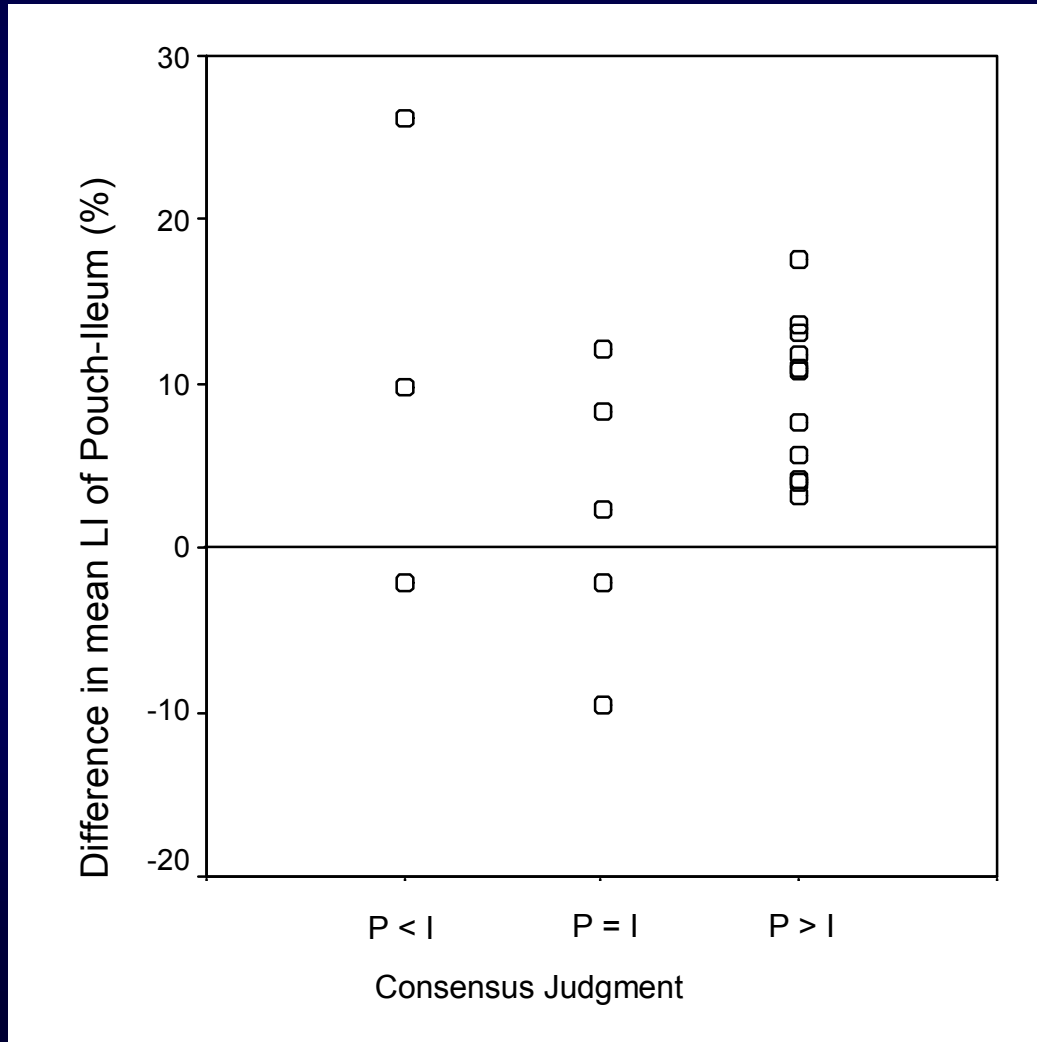




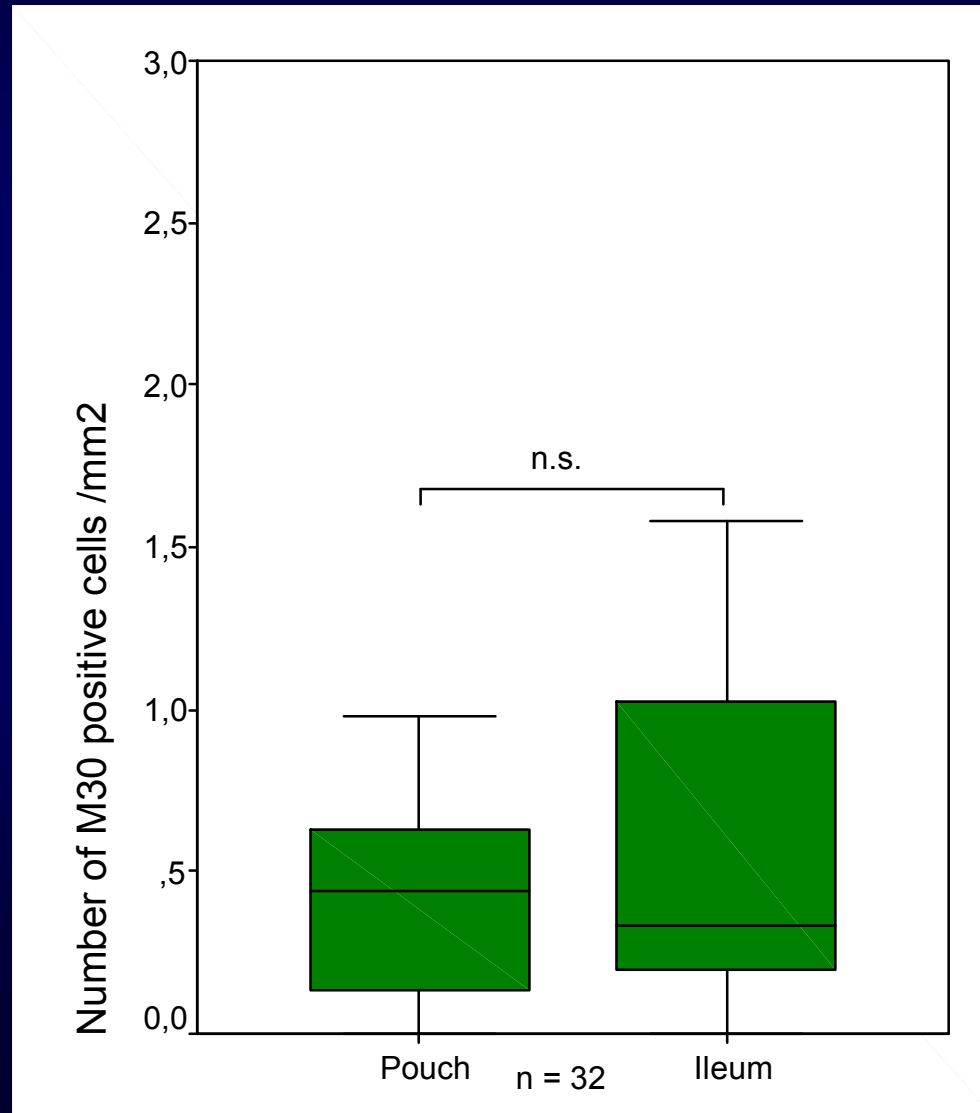
Cell Proliferation: Qualitative Method



Cell Proliferation: Qualitative Method



Apoptosis



Colonic Metaplasia

	Median	Range
Crypt hyperplasia (0 - 3)	0	0 - 3
Villous atrophy (0 - 3)	0	0 - 3
Colonic metaplasia (0 - 6)	0	0 - 6

Inflammation

		Median	Range
Crypt	Neutrophils (0 - 3)	0	0 - 1
	Lymphocytes (0 - 3)	0	0 - 2
Villi	Neutrophils (0 - 3)	0	0 - 2
	Lymphocytes (0 - 3)	0	0 - 2
Stroma	Neutrophils (0 - 3)	0	0 - 2
	Lymphocytes (0 - 3)	0	0 - 2
	Plasma cells (0 - 3)	1	0 - 3
	Eosinophils (0 - 3)	1	0 - 3
Total Inflammation	(0 - 24)	4	0 - 9

Inflammation

		Median	Range
Crypt	Neutrophils (0 - 3)	0	0 - 1
	Lymphocytes (0 - 3)	0	0 - 2
Villi	Neutrophils (0 - 3)	0	0 - 2
	Lymphocytes (0 - 3)	0	0 - 2
Stroma	Neutrophils (0 - 3)	0	0 - 2
	Lymphocytes (0 - 3)	0	0 - 2
	Plasma cells (0 - 3)	1	0 - 3
	Eosinophils (0 - 3)	1	0 - 3
Total Inflammation (0 - 24)		4	0 - 9

Conclusions

- Compared to the afferent ileal loop, pouch mucosa proliferation is increased in FAP patients
- This is not explained by colonic metaplasia or pouch mucosa inflammation
- Visual estimation of mucosal proliferation (qualitative method) is a rapid and reliable method
- No change in mucosal apoptosis occurs

Discussion

- Altered cell kinetics in the pouch of FAP patients
 - may be responsible for the enhanced adenoma (and carcinoma) formation and emphasizes the need for endoscopic surveillance
 - can be used as intermediate endpoint marker in chemoprevention trials

Acknowledgments

- Bjorn van Heumen
- Marloes Berkhout
- Wilbert Peters
- Han van Krieken
- Fokko Nagengast



